

Case Report

“The Baltic Sea Germ”: A Case Report of Necrotizing Fasciitis following *Vibrio vulnificus* Infection

Heinz-Lothar Meyer ¹, Christina Polan,¹ Manuel Burggraf ¹, Lars Podleska,² Paula Beck,¹ Hans-Ulrich Steinau,¹ Marcel Dudda,¹ and Farhad Farzaliyev^{1,2}

¹Department for Trauma, Hand and Reconstructive Surgery, Essen University Hospital, Hufelandstraße 55 45147 Essen, Germany

²Department for Tumor Orthopedics and Sarcoma Surgery, Essen University Hospital, Hufelandstraße 55 45147 Essen, Germany

Correspondence should be addressed to Heinz-Lothar Meyer; heinz-lothar.meyer@uk-essen.de

Received 21 November 2021; Revised 22 February 2022; Accepted 7 March 2022; Published 23 March 2022

Academic Editor: Johannes Mayr

Copyright © 2022 Heinz-Lothar Meyer et al. This is an open access article distributed under the Creative Commons Attribution License, which permits unrestricted use, distribution, and reproduction in any medium, provided the original work is properly cited.

Reported is an 80-year-old patient with septic shock from necrotizing fasciitis secondary to a *Vibrio vulnificus* (Vv) infection. The patient reports having been swimming in the Baltic Sea after a minor trauma to the left leg. Emergency superficial necrosectomy followed by intensive medical therapy was performed. Antibiotic therapy was initiated with a third-generation cephalosporin and a tetracycline. Vv was detected in the intraoperative microbiological smears. Instead of a leg amputation and a flap, due to the patient's age, a split skin covering to consolidate the wound was performed. Vv is a gram-negative rod bacterium of the genus *Vibrio*. Vv occurs in warm, low-salinity seawater (brackish water). In Germany, Vv occurs primarily in river mouths of the low-salinity Baltic Sea. Infections by Vv can occur through open wounds or by eating raw infected seafood, especially oysters. Infection via wounds often take a fulminant lethal course. Patients with chronic diseases, weakened immune system, and open wounds are particularly at risk. Infections with Vv are rare, but occur worldwide. Global warming is expected to spread Vv as water temperature increases and the dilution effect of sea level rise further decreases ocean salinity, and natural disasters promote the spread of Vv.

1. Introduction

Vibrio vulnificus (Vv) is a gram-negative rod-shaped bacterium of the genus *Vibrio*. Vv occurs naturally in warm and low-salt seawater or brackish water [1–3]. In Germany, Vv is found especially in river mouths of the low-salt Baltic Sea. A low salt concentration is ideal for growth, as found in the Baltic Sea [4]. Therefore, in studies of Baltic Sea estuaries, Vv was detected in significantly more samples than in samples from the North Sea [5]. Infections with Vv are rare but occur worldwide. Vv exists in an inactive state at cold water temperatures, such as those present in winter [6, 7]. If water temperature rises above 20°C in summer, Vv is activated. Once activated, the bacterium can maintain its activity for several weeks even when water temperatures drop [6, 7]. Vv infections can occur by swimming or wading in contaminated waters. The bacteria can enter through open

wounds in the skin [2, 8]. A second route of transmission is the consumption of raw infected seafood, especially oysters [5, 9]. Symptoms following consumption of infected seafood include vomiting, diarrhea, abdominal pain, and blistering dermatitis [10]. The less common infection via wounds often takes a serious course to sepsis with a rapidly fulminant progression to septic shock [11]. Patients with chronic diseases, weakened immune system, and open wounds are particularly at risk. Older, male individuals with chronic liver disease, immunosuppression, or diabetes mellitus are the typical risk group for Vv infection and a fulminant course [6, 12]. Often, the affected extremities have to be amputated. The lethality of Vv infections is reported in the literature to approximately 25%. If the infection progresses to sepsis, the lethality rate increases to over 50%. Most deaths occur within the first 48 hours of infection [13]. There is no guideline treatment for Vv infection. A

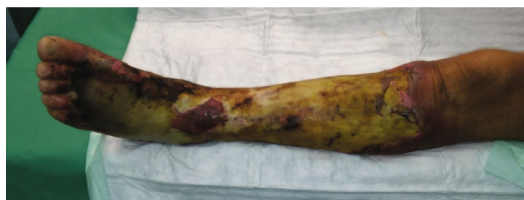

FIGURE 1: Necrotizing fasciitis of the left lower leg with Vv.

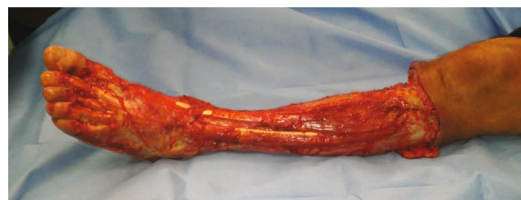

FIGURE 2: After emergency superficial necrosectomy of the necrotizing fasciitis of the left lower leg.

study from Taiwan demonstrated that the combined use of a third-generation cephalosporin with tetracyclines was associated with a better outcome [14, 15]. The most frequent reports come from the USA (East Coast), Japan, and Taiwan [13, 16]. In this case report, we present a fulminant Vv infection of the lower limb that was successfully treated without amputation, hence developing a highly differentiated squamous cell carcinoma of the affected limb in the long-term after split skin graft and chronic lymphedema four years after surviving the infection.

2. Case Presentation

Presented is a case of an 80-year-old patient who was on holiday on the German Baltic coast in September. He recalled a minor trauma to his left leg prior to swimming in the Baltic Sea several times. Afterwards, he noticed an infection in the area of the left lower leg, which rapidly developed into necrotizing fasciitis and septic shock. Initial treatment at the local hospital only consisted of superficial debridement. Subsequently, the patient was transferred to our hospital for further treatment. Due to the vital threat, an emergency necrosectomy was performed for necrotizing fasciitis of the left lower leg (Figures 1 and 2) followed by intensive care therapy. Antibiotic therapy was continued with Meronem and Clindamycin. Vv was detected in the microbiological swabs obtained intraoperatively. Instead of a leg amputation and a flap, due to the patient's age, a split skin covering to consolidate the wound was performed (Figures 3 and 4). Only areas in the dorsal region of the left foot and in the ventral region of the tibialis anterior tendon showed failed split skin grafts. Here, tangential ablation of the fibrin-covered tendons was performed at regular intervals. These areas granulated secondarily. After a two-month hospital stay, the patient was able to leave the clinic standing and walking safely (Figure 5). Four years after the initial vibriosis infection, the patient exhibited an inconspicuous wound situation in the area of the skin graft region of the lower leg that had otherwise healed without irritation up to the ankles. The area of the forefoot at the metatarsophalangeal joints showed an approximately 7×4 cm large, smelly, and granulating wound surface on the extensor side. In the further course, hypergranulation tissue appeared on the dorsum of the left foot (Figure 6). Surgical resection of the hypergranulation tissue and covering of the defect with split skin of the left foot was performed. Histopathologic analysis of the intraoperative tissue samples ultimately resulted in the finding of the highly differentiated squamous cell carcinoma on the dorsum of the left foot of the affected limb after split

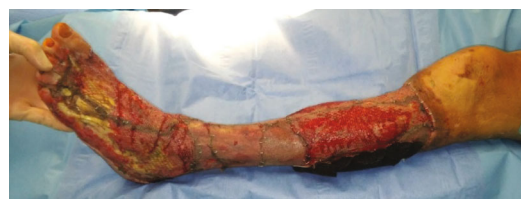

FIGURE 3: Left lower leg after the first split skin graft.

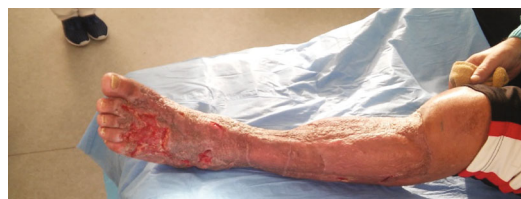

FIGURE 4: Left lower leg 3 months after split skin graft.

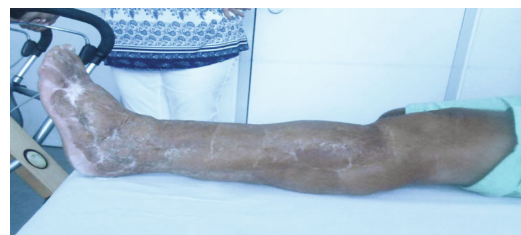


FIGURE 5: Two years after necrotizing fasciitis of the left lower leg with Vv.

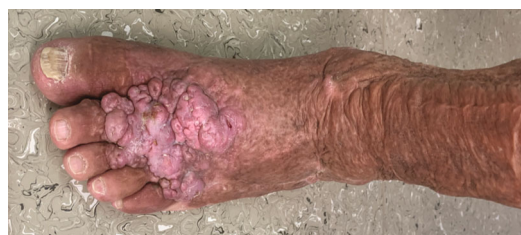

FIGURE 6: Highly differentiated squamous cell carcinoma of the skin on the dorsum of the left foot of the lower leg, four years after an infection by Vv.

skin graft and chronic lymphedema (Figures 6, 7(a), and 7(b)). The primary was excised. In the further course, the patient could be released into the home environment

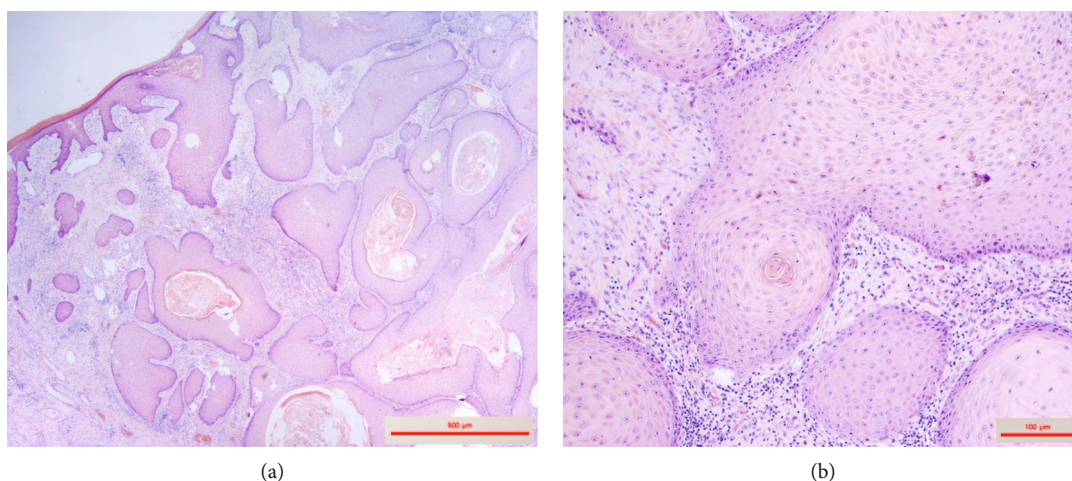


FIGURE 7: Histopathology Hematoxylin Eosin (HE) staining of the differentiated squamous cell carcinoma four years after surviving infection in the affected extremity.

after an early rehabilitation. A follow-up one year later showed another recurrence of the highly differentiated squamous cell carcinoma on the dorsum of the left foot which was excised again.

3. Discussion

The presented case shows a vital threatening Vv infection with an extremity-preserving therapy. The fulminant course in this patient shows the possible danger of Vv infections. Due to global warming, the water temperature of the oceans is increasing. The polar ice caps are melting, causing sea levels to rise and a dilution effect to reduce the salt concentration of the oceans [6]. The German Baltic coast is one of the most vulnerable areas due to low salinity and increasing warming. A review article by Baker-Austin et al. already discussed some increase in Vv cases in the Baltic Sea area as a result of climate change [17]. After the increasing number of natural disasters (floods, hurricanes, etc.), Vv can be detected in the flood plains [18]. As a result, infections caused by Vv can be expected to increase in the coming decades. Furthermore, Vv is the most common pathogen for infections with a lethal outcome associated with seafood consumption in the United States. There are increasing numbers in multidrug-resistant Vv to antibiotics in seafood. This has been attributed to the increase in fish and shellfish farms [9]. Since 1985, the annual numbers of Vv infections registered in Germany have also been steadily increasing. In particular, the above mentioned risk groups should be made more aware of the danger in the next years and medical doctors in the corresponding regions should be sensitized to it [8, 19]. This is especially true with regard to the affected regions in Germany where many health resorts are located, and thus, many people at risk are exposed to a possible Vv infection [20]. Regarding malignant degeneration in the long-term course, studies have already shown that squamous cell carcinomas have formed after split skin grafts. This applies to both the donor and the transplant site, regardless of the region of the body [21, 22]. The same has

been observed in areas of the body with chronic lymphedema [23]. Hence, in the context of Vv infection, this association has not yet been adequately described or refuted in the literature. In the presented case, due to the extremity preserving procedure with large area split skin grafts after necrosectomy instead of amputation of the affected limb, the patient's initial quality of life certainly was significantly improved. Nevertheless, appropriate patient education seems at least highly recommendable.

Data Availability

The patient presented has agreed to the anonymous presentation of his medical history.

Conflicts of Interest

The authors declare no potential conflicts of interest with respect to the research, authorship, and/or publication of this article.

Authors' Contributions

All authors read and approved the final manuscript.

References

- [1] J. D. Oliver, "Wound infections caused by *Vibrio vulnificus* and other marine bacteria," *Epidemiology and Infection*, vol. 133, no. 3, pp. 383–391, 2005.
- [2] M. K. Jones and J. D. Oliver, "Vibrio vulnificus: Disease and pathogenesis," *Infection and Immunity*, vol. 77, no. 5, pp. 1723–1733, 2009.
- [3] M. H. Bross, K. Soch, R. Morales, and R. B. Mitchell, "Vibrio vulnificus infection: diagnosis and treatment," *American Family Physician*, vol. 76, no. 4, pp. 539–544, 2007, PMID: 17853628.
- [4] C. W. Kaspar and M. L. Tamplin, "Effects of temperature and salinity on the survival of *Vibrio vulnificus* in seawater and shellfish," *Applied and Environmental Microbiology*, vol. 59, no. 8, pp. 2425–2429, 1993.

- [5] N. Bier, C. Jäckel, R. Dieckmann, N. Brennholt, S. I. Böer, and E. Strauch, "Virulence profiles of *Vibrio vulnificus* in German coastal waters, a comparison of North Sea and Baltic Sea isolates," *International Journal of Environmental Research and Public Health*, vol. 12, no. 12, pp. 15943–15959, 2015.
- [6] B. A. Craig and D. O. James, "Vibrio vulnificus: new insights into a deadly opportunistic pathogen," *Environmental Microbiology*, vol. 20, no. 2, pp. 423–430, 2018.
- [7] K. Kuhnt-Lenz, S. Kregel, S. Fetscher, A. Heer-Sonderhoff, and W. Solbach, "Sepsis with bullous necrotizing skin lesions due to vibrio vulnificus acquired through recreational activities in the Baltic Sea," *European Journal of Clinical Microbiology & Infectious Diseases*, vol. 23, no. 1, pp. 49–52, 2004, Epub 2003 Dec 4.
- [8] C. Frank, M. Littman, K. Alpers, and J. Hallauer, "Vibrio vulnificus wound infections after contact with the Baltic Sea, Germany," *Euro Surveillance*, vol. 11, no. 33, 2006.
- [9] S. Elmahdi, S. Parveen, S. Ossai et al., "Vibrio parahaemolyticus and Vibrio vulnificus recovered from oysters during an oyster relay study," *Applied and Environmental Microbiology*, vol. 84, no. 3, 2018.
- [10] S. I. Miyoshi, "Vibrio vulnificus infection and metalloprotease," *The Journal of Dermatology*, vol. 33, no. 9, pp. 589–595, 2006, PMID: 16958802.
- [11] G. Li and M. Y. Wang, "The role of Vibrio vulnificus virulence factors and regulators in its infection-induced sepsis," *Folia Microbiologica*, vol. 65, no. 2, pp. 265–274, 2020.
- [12] J. Park and C. S. Lee, "Vibrio vulnificus Infection," *New England Journal of Medicine*, vol. 379, no. 4, p. 375, 2018.
- [13] R. Horré, S. Becker, G. Marklein et al., "Necrotizing fasciitis caused by Vibrio vulnificus: first published infection acquired in Turkey is the second time a strain is isolated in Germany," *Infection*, vol. 26, no. 6, pp. 399–401, 1998.
- [14] J. W. Liu, I. K. Lee, H. J. Tang et al., "Prognostic factors and antibiotics in Vibrio vulnificus septicemia," *Archives of Internal Medicine*, vol. 166, no. 19, pp. 2117–2123, 2006.
- [15] F. Leng, S. Lin, W. Wu, J. Zhang, J. Song, and M. Zhong, "Epidemiology, pathogenetic mechanism, clinical characteristics, and treatment of Vibrio vulnificus infection: a case report and literature review," *European Journal of Clinical Microbiology & Infectious Diseases*, vol. 38, no. 11, pp. 1999–2004, 2019.
- [16] P. R. Hsueh, C. Y. Lin, H. J. Tang et al., "Vibrio vulnificus in Taiwan," *Emerging Infectious Diseases*, vol. 10, no. 8, pp. 1363–1368, 2004.
- [17] V. J. Noori, K. Trehan, A. Savetamal, and D. W. Carter, "New onset squamous cell carcinoma in previous split-thickness skin graft donor site," *International Journal of Surgery*, vol. 52, pp. 16–19, 2018.
- [18] D. N. Steffanoff, "Late development of squamous cell carcinoma in a split-skin graft lining a vagina," *Plastic and Reconstructive Surgery*, vol. 51, no. 4, pp. 454–456, 1973.
- [19] C. A. Gomes, C. B. Magalhães, C. Soares Jr., and R. O. Peixoto, "Squamous cell carcinoma arising from chronic lymphedema: case report and review of the literature," *São Paulo Medical Journal*, vol. 128, no. 1, pp. 42–44, 2010.
- [20] C. Baker-Austin, J. Trinanes, N. Taylor, R. Hartnell, A. Siitonen, and J. Martinez-Urtaza, "Emerging Vibrio risk at high latitudes in response to ocean warming," *Nature Climate Change*, vol. 3, no. 1, pp. 73–77, 2013.
- [21] K. Esteves, D. Hervio-Heath, T. Mosser et al., "Rapid proliferation of Vibrio parahaemolyticus, Vibrio vulnificus, and Vibrio cholerae during freshwater flash floods in French Mediterranean coastal lagoons," *Applied and Environmental Microbiology*, vol. 81, no. 21, pp. 7600–7609, 2015.
- [22] C. Metelmann, B. Metelmann, M. Gründling, K. Hahnenkamp, G. Hauk, and C. Scheer, "Vibrio vulnificus, eine zunehmende Sepsisgefahr in Deutschland?," *Anaesthesist*, vol. 69, no. 9, pp. 672–678, 2020, PMID:32620988.
- [23] S. Huehn, C. Eichhorn, S. Urmsbach et al., "Pathogenic vibrios in environmental, seafood and clinical sources in Germany," *International Journal of Medical Microbiology*, vol. 304, no. 7, pp. 843–850, 2014.

DuEPublico

Duisburg-Essen Publications online

UNIVERSITÄT
DUISBURG
ESSEN

Offen im Denken

ub | universitäts
bibliothek

This text is made available via DuEPublico, the institutional repository of the University of Duisburg-Essen. This version may eventually differ from another version distributed by a commercial publisher.

DOI: 10.1155/2022/5908666

URN: urn:nbn:de:hbz:465-20220812-082449-1



This work may be used under a Creative Commons Attribution 4.0 License (CC BY 4.0).