Original Article

Cephalalgia
An International Journal of Headache
International Headache Society

Cephalalgia
2022, Vol. 42(4–5) 335–344

DOI: 10.1177/03331024211045653
journals.sagepub.com/home/cep
SAGE

No structural brain alterations in new daily persistent headache – a cross sectional VBM/SBM study

Steffen Naegel[1,2,*], Julia Zeller[2,3,*], Anders Hougaard[4], Christopher Michael Weise[1], Hans-Christoph-Diener[5], Stefan Zuelow[6,7], Christoph Kleinschnitz[1], Mark Obermann[2,8], Kasja Solbach[2] and Dagny Holle[2]

Abstract

Objective: To identify grey matter alterations in patients suffering new daily persistent headache to enrich the pathophysiological concept of this rare headache disorder characterised by a distinct, clearly remembered onset and its instant chronification.

Method: Magnetic resonance-based voxel-based and surface-based morphometry was used to investigate 23 patients suffering from new daily persistent headache and 23 age- and gender-matched healthy controls with 1.5 Tesla MRI. Independent statistical analysis was performed at three sites using statistical parametric mapping, as well as FSL(FMRIB Software Library)-based approaches.

Results: No grey matter changes were detected using this sophisticated and cross-checked method.

Conclusion: The absence of structural brain changes in patients with new daily persistent headache contribute to the recent discussion regarding structural alterations in primary headache disorders in general and does not provide evidence for grey matter changes being associated with the pathophysiology of new daily persistent headache. Future research will have to determine the underlying pathophysiological mechanisms of this disorder.

Keywords

New daily persistent headache, voxel-based morphometry, brain structural correlate

Date received: 12 April 2021; revised: 12 August 2021; accepted: 16 August 2021

Introduction

New daily persistent headache (NDPH) is a very rare primary headache disorder with an estimated prevalence of 0.03% (1). It was first described by Vanast in 1986 and was characterised by its distinct onset and a

[1]Department of Neurology, Martin-Luther-University Halle-Wittenberg, Halle/Saale, Germany
[2]Department of Neurology, Westgerman Headache Center, University of Duisburg-Essen, University Hospital Essen, Essen, Germany
[3]Paediatric Haematology and Oncology, Paediatrics III, University of Duisburg-Essen, University Hospital Essen, Essen, Germany
[4]Danish Headache Center, Department of Neurology, Rigshospitalet Glostrup, Faculty of Health and Medical Sciences, University of Copenhagen, Copenhagen, Denmark
[5]Institute for Medical Informatics, Biometry and Epidemiology, Medical Faculty of the University Duisburg-Essen, Essen, Germany
[6]Department of Diagnostic and Interventional Radiology and Neuroradiology, University of Duisburg-Essen, University Hospital Essen, Essen, Germany
[7]Department of Diagnostic and Interventional Radiology and Neuroradiology, Rheinische Friedrich-Wilhelms-Universität, Bonn, Germany
[8]Department of Neurology, Klinikum Weser-Egge, Höxter, Germany

*These authors contributed equally to this work.

Corresponding author:
Steffen Naegel, Department of Neurology, Martin-Luther-University Halle-Wittenberg, Ernst-Grube-Str. 40, 06120 Halle (Saale), Germany.
Email: steffen.naegel@medizin.uni-halle.de

primary chronic/persistent course (2). In 2004, NDPH was included in the second edition of the International Classification of Headache Disorders (ICHD-2) (3). In this first version of the classification, it was defined as headache fulfilling the characteristics of tension-type headache (TTH) becoming daily and unremitting within 3 days from onset. ICHD-3 beta modified the criteria by allowing more flexibility regarding the headache characteristics (including migrainous features) but highlighted the distinct and clearly remembered onset of pain, which is now defined as continuous and unremitting within 24 hours.

According to published case reports, most patients with NDPH do not report a previous history of headaches, although presence of other headache disorder does not rule out NDPH. The clinical presentation of NDPH may be very diverse. This led to the question of whether it is truly a unique headache entity or merely a symptom of other, underlying disorders (4). Indeed, different triggers including recent infection, stress and trauma were discussed in this regard, but could not be determined in every single case (5). The pathophysiology of NDPH remains unclear.

Previously structural brain imaging was utilised in several different primary headache disorders to investigate their underpinnings. Starting in 1999, May and colleagues were the first to identify brain structural alterations in cluster headache (6). Although later studies were not constantly able to reproduce the observed hypothalamic grey matter loss, these early findings formed the foundation of brain structural alterations as correlate of brain malfunction, as alterations were in line with pathophysiological concepts and previously reported activation in functional imaging (7–9).

Furthermore, this motivated researchers to investigate different pain and headache disorders (e.g. migraine (10,11), tension type headache (12), medication overuse headache (13–15)) and processes like chronification using voxel-based morphometry (VBM) (16). Results were not always congruent and partly even divergent. Parallel to identified "specific" alterations, a common thread, however, was that that pain appears to be associated with grey-matter (GM) volume decrease in several brain areas. Furthermore, changes appeared to be reversible with cessation of pain (17–19). Only very little is known regarding the underlying pathophysiological mechanisms, and even short-term stimulation was able to induce alterations identifiable using VBM (20). Both make interpretation challenging. Nevertheless, the technique is capable of identifying structural changes and is thus suitable for generation and testing of hypotheses.

The aim of our study was to detect grey matter changes in NDPH to enrich the knowledge regarding underlying mechanisms of the disease.

Material and methods

Subjects

Twenty-eight patients with NDPH were recruited between 2012 and 2015 in the West German Headache Centre Essen, a tertiary headache clinic, which is part of the Department of Neurology of the University Hospital Essen.

The diagnosis in every single case was established or reconfirmed by a headache-experienced neurologist according to the ICHD- 2 (valid at the start of the study) (3). As during recruitment ICHD-3 beta was released, this was adopted. All patients recruited until March 2013 were re-evaluated to fulfill ICHD-3 beta criteria, which were later taken over into ICHD-3 (21,22). After March 2013, all patients were recruited directly applying ICHD-3 criteria. Exclusion criteria for patients were any other headaches (e.g. medication overuse headache (MOH) and medication overuse in general, tension-type headache (TTH), migraine, and hemicrania continua), as well as other serious somatic or psychiatric diseases.

The control cohort was predefined as an age- and sex-matched group of the exact same size and was recruited from the patients' families and friends, as well as via posters on the campus. Healthy control (HC) subjects were only allowed to participate if they did not suffer any relevant headache (they were only eligible when suffering tension-type headache with a frequency of at maximum one headache day per month during the last 6 months). Subjects suffering from other headache disorders (e.g. migraine) were not allowed in this study.

General exclusion criteria for patients and HC were age under 18 years, other pain conditions, as well as severe psychiatric and somatic illnesses.

The study protocol was approved by the local ethics committee and all participants gave their written informed consent in accordance with the fundamental ethical principles laid down in the Declaration of Helsinki prior to study inclusion.

Clinical and demographic data

All patients included were interviewed using a standardised questionnaire addressing headache presentation, past medical history, beginning of symptoms, family history, possible causes, changes in quality of life and psychiatric comorbidities. Additionally, patients were asked to fill out the questionnaire to explore the Hospital Anxiety and Depression Scale (HADS), Beck Depression Inventory II (BDI-II), Migraine Disability Assessment, German version (MIDAS), and Headache Impact Test (HIT 6).

Statistical analysis of demographic data, collected scores, and brain tissue volumes were carried out using IBM SPSS Statistics Version 22 (International Business Machines Corporation, Armonk, New York, USA) applying Student's t-test with a cutoff significance level of $p < 0.05$. Categorical variables were tested using Fisher's exact test.

MRI data acquisition, processing, and analysis

Imaging of all participants was performed on a 1.5 Tesla MRI scanner (Magnetom Avanto, Siemens Healthcare, Erlangen, Germany) using a standard 8-channel birdcage head coil. Prior to analysis, all images were rated regarding image quality and pathologies. This was double-checked by an experienced neuroradiologist (SZ) blinded to the diagnosis. Only scans rated unremarkable in terms of quality and pathology were included in the analysis. T1-weighted magnetic resonance imaging (MRI) 3D datasets were obtained using a magnetisation prepared rapid acquisition gradient echo (MP-RAGE) sequence (TR: 2400 ms, TE: 3.52 ms, TI: 1200 ms, flip angle: 8, matrix $256 \times 256\,mm^2$, 160 slices, voxel size: $1 \times 1 \times 1\,mm^3$).

VBM preprocessing and statistical analysis was performed three times. The primary analysis utilising SPM12 (Wellcome Trust Centre for Neuroimaging, UCL, London, UK [http://fil.ion.ucl.ac.uk]) + CAT12 Toolbox (http://www.neuro.uni-jena.de/cat/) and a second analysis using the older software iteration (SPM8, VBM as proposed by John Ashburner) were performed at site 1 (Essen, Germany). The second analysis was performed as control, as this setup (scanner, sequence and analysis) proved to deliver reliable results in the past (7). A third analysis was done by a blinded, independent analyser (AH) at site 2 (Glostrup, Denmark) using FSL-based VBM analysis.

Additionally, surface-based morphometry (SBM) was performed retrospectively using SPM12 + CAT12 Toolbox at site 3 (Halle, Germany).

SPM-based VBM analysis

Data processing and analysis was performed using statistical parametric mapping (SPM) and Matlab (Matlab 7.6.0.324, R2008a, MathWorks, Natick, MA, USA).

Primary analysis was done using SPM12 and the CAT12 Toolbox.

A second analysis was carried out from scratch using SPM8 including "New Segment", "DARTEL" (23) and preprocessing involved "unified segmentation" (including normalisation into the Montreal Neurological Institute (MNI) space) and modulation to adjust for volume changes during spatial normalisation (24–27). Spatial smoothing was performed with an isotropic Gaussian kernel of 10 mm full width at half maximum (28).

Statistical whole brain analysis tested GM volume differences between NDPH patients and HC for both approaches. Although gender and age matching was performed, these factors were also included into the statistical model along with total intracranial volume (TIV). The threshold for significant grey matter alterations was predefined at $p_{FWE} < 0.05$ with correction for multiple comparison (family-wise error = FWE, on cluster and peak level). To avoid unintentional bias by *a priori* hypothesis, to have better comparability to previous pain VBM studies, and not to miss any false negative results, a less conservative exploratory threshold without a correction for multiple comparisons (unc = uncorrected) of $p\text{-}_{unc} < 0.001$ and a voxel threshold >10 voxels was additionally tested.

Volumes of different brain tissue classes and total intracranial volume (TIV) were estimated by CAT12. T-tests investigating differences in tissue classes volumes were carried out using SPSS.

Blinded FSL-based VBM analysis

Forty-six 3D T1-weighted MR images of 46 research subjects (numbered 1–56) and corresponding age and gender information for each subject was sent to Glostrup, Denmark, for reconfirmation of the study results. No additional clinical information was provided.

Data were analysed with FSL-VBM (http://fsl.fmrib.ox.ac.uk/fsl/fslwiki/FSLVBM) (29), an optimized VBM protocol (30) carried out with FSL tools (31). The FSL analysis pipeline was derived directly from the FSL user guide. First, structural images were brain extracted and grey-matter segmentation was performed before the images were registered to the MNI 152 standard space using non-linear registration. The resulting images were averaged and flipped along the x-axis to create a left-right symmetric, study-specific grey-matter template. Second, all native grey-matter images were non-linearly registered to this study-specific average template and "modulated" to correct for local expansion or contraction due to the non-linear component of the spatial transformation. The modulated grey matter images were then smoothed with an isotropic Gaussian kernel with a sigma of 3 mm; that is, approximately full width half maximum (FWHM) of $3 \times 2.3 = 6.9$ mm (https://fsl.fmrib.ox.ac.uk/fsl/fslwiki/FSLVBM).

Group A (subjects numbered 1–28) was compared to Group B (subjects numbered 29–56) in an unpaired two-group design in a voxel-wise general linear model (GLM) using permutation-based non-parametric

testing (32) correcting for multiple comparisons across space by threshold-free cluster enhancement (TFCE, cluster-wise $p < 0.05$) (33). Age and gender were included in the model as nuisance variables.

SPM-based surface analysis

For SBM analyses of cortical thickness (CTH), cortical complexity reflected by fractal dimension (FA), gyrification index (GI), and sulcal depth (SDept) the automated surface-preprocessing algorithms implemented in the CAT12 toolbox were applied. Using projection-based thickness enables parallel computation of cortical thickness and reconstruction of the central surface including partial volume correction, correction for sulcal blurring, and correction for sulcal asymmetries (34). Following the recommendation of the CAT12 authors, surface-based cortical thickness data of both hemispheres were merged and smoothed with a 12 mm FWHM isotropic Gaussian kernel. Folding data were smoothed with a 25 mm FWHM isotropic Gaussian kernel.

Only gender and age were included into the statistical model, as for surface-based data no correction for TIV is required. As in SPM-based VBM, the primary threshold for significant alterations was defined at $p_{FWE} < 0.05$ with correction for multiple comparison (family-wise error = FWE, on cluster and peak level). Additionally, TFCE (FWE < 0.05) was performed with 5000 permutations using the TFCE toolbox (http://www.neuro.uni-jena.de/tfce/).

Post hoc – power analysis

As the effect size of possible structural alterations is not known in NDPH, no *a priori* power analysis was performed. For exploratory purposes we used GPower (V 3.1.9.6) to calculate the statistical power post hoc (35). To identify candidate regions, a lowered threshold (uncorrected $p < 0.005$) was applied to the SPM VBM data. For both increase and decrease of GM, the region with the highest T value in line with previously reported alteration in headache was identified. Cohen's d was then calculated for this local maximum and post-hoc power was calculated using GPower with an alpha error probability of 0.05. Additionally, the virtually necessary sample size was calculated retrospectively using the *a priori* approach applying a power of 0.95, a two-tailed analysis and a one-to-one matching. To put this into perspective, this was additionally done for three other headache disorders, previously published (7,16,36). Here regions with highest T values and significant with a threshold $p_{FWE} < 0.05$ were used.

Results

Thirty-six patients suffering NDPH could be identified (18 men, 18 women), of which 28 were eligible and willing to be part of the MRI study. Five patients and one control were excluded due to different structural alterations (e.g. subcortical vascular encephalopathy, brain volume loss, pinealis cysts or Rathke's pouch cyst, inspection performed by SZ). Following the predefined matching 23 patients (13 men, 10 women) and 23 initially matched control subjects were included in the final analyses. Figure 1 gives an overview of the recruitment and exclusion of participants. Clinical characteristics and demographics of these are shown in Table 1. Patients were compared to 23 healthy age- and gender-matched controls. As NDPH is a persistent headache, all patients suffered from headache during the scanning procedure.

Clinical characteristics and demographics

Average age of the patients was 44.91 ± 15.61 years (range 18–69), HC did not differ significantly in age and were on average 44.70 ± 14.75 years old (21–70). Average age at onset of disease was 40.0 years (16–62 years, SD = ±15.04). In all patients, headache was present continuously. Fourteen of 23 patients (60.9%) remembered the exact date of onset, all remembered that the headache had an abrupt onset. A total of 73.9% of patients specified a moderate intensity of pain (categorised as mild, moderate and severe). Using a numeric rating scale (NRS) from 0–10 (0 = no pain, up to 10 = worst imaginable pain) the average intensity was 5.30 ± 1.66 (2–8). The median duration of NDPH was 30 months ranging from 3–324 months.

Regarding clinical presentation and based on ICHD-3, we subdivided the patients into three groups (tension-type headache (TTH), migraine-like subtype (CM), and probable migraine (PM)). Most patients fulfilled characteristics of TTH (60.9%), while only three patients showed migrainous symptoms (17.4%). Five patients could not be strictly categorised to TTH or CM, but could be assigned to a "probable migraine" subtype (21.7%).

All patients had used analgesics for acute treatment of their headache in the past, although mostly unsuccessfully (73.9%). No patient had medication overuse. Eighty-seven percent of the patients were already on prophylactic medication, which was effective in terms of intensity reduction in 11 of 21 patients (52.3%). Details of headache characteristics and collected scores are given in Table 2.

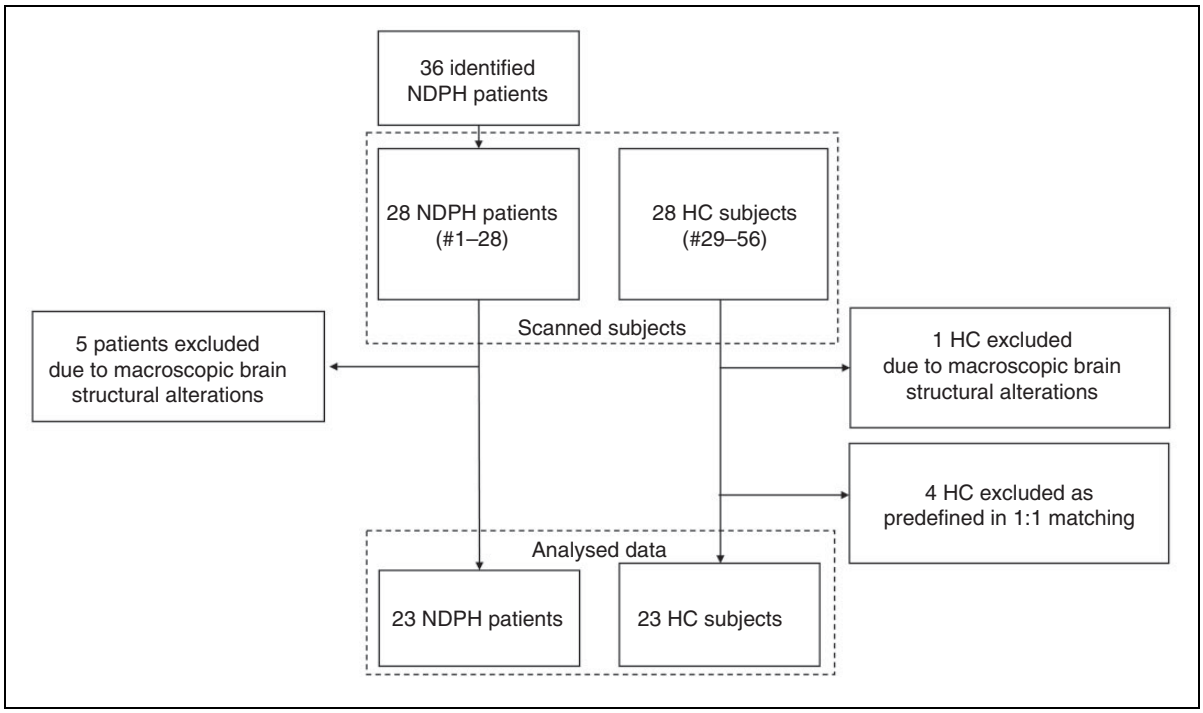

Figure 1. Illustration of the recruitment and exclusion process.
NDPH: new daily persistent headache; HC: healthy controls; #: number.

Table 1. Demographic and basic MRI data.

	NDPH	HC	*p*
Age ± SD (years) (Range)	44.91 ± 15.61(18–69)	44.70 ± 14.75 (21–70)	0.962
Sex (M/F)	13/10	12/11	0.777+
GM ± SD (millilitres) (Range)	333.57 ± 61.40 (262–486)	332.78 ± 4814 (212–413)	0.962
TIV ± SD (millilitres) (Range)	1581 ± 176 (1343–2011)	1540 ± 115 (1275–1773)	0.356

Note: Comparison of demographic and MRI data of NDPH patients and healthy control subjects.
Statistics: Student's t-test; + = Fisher's exact test. NDPH: new daily persistent headache; GM: grey matter volume, TIV: total intracranial volume (composed of grey matter, white matter, and cerebral spinal fluid).

SPM – voxel-based morphometry

In all 46 MRIs included in the final analysis, no further morphological abnormalities or artifacts were observed in the independent visual inspection (SN).

Neither the first (SPM12 + CAT12) nor the second SPM-based analysis (SPM8) was able to identify any GM alterations comparing patients with HC. This accounts for both applied significant thresholds (FWE and uncorrected). The additionally performed t-test of different brain tissue classes volumes (GM/WM/CSF/TIV) also did not reveal significant differences in NDPH patients compared to controls.

FSL analysis – voxel-based morphometry

Prior to FSL analysis, the blinded rater (AH) again checked the images visually and found image quality to be excellent in all scans. Regarding pathologies and in accordance with preselection (SZ), no obvious structural abnormalities were seen in any of the images. The above-described VBM process completed without errors within the first run. No clusters of significantly greater grey matter intensity in Group A compared to Group B ($p > 0.47$) and no clusters of significantly greater grey matter intensity in Group B compared to Group A ($p > 0.78$) were detected.

Surface-based morphometry – SPM

Neither for CTH, nor for any of the folding data (FA, GI, SDept) comparison of patients and HC was it possible to identify any differences. This accounts for both applied significant thresholds.

Table 2. Clinical characteristics of NDPH patients.

Age at onset ± SD (range, years)	40.0 ± 15.0 (16–62)
Headache intensity	
Mild	4.3% (1/23)
Moderate	73.9% (17/23)
Severe	21.7% (5/23)
NRS (0–10) ± SD	5.30 ± 1.66
Headache location	
Bilateral ♦ unilateral	
Headache character	
Throbbing	8.7% (2/23)
Pressing	78.3% (18/23)
Other	13.0% (3/23)
Accompanying symptoms	
Subtypes	
Phonophobia	30.4% (7/23)
Photophobia	30.4% (7/23)
Nausea	21.7% (5/23)
History of headache	21.7% (5/23)
Migraine ♦ TTH	13.0% (3/23) ♦ 8.7% (2/23)
Positive family history	13.0% (3/23)
Migraine-like	17.4% (4/23)
TTH-like	60.9% (14/23)
Probable migraine-like	21.7% (5/23)
Psychometric values	
BDI II	12.35 ± 7.61
HADS	7.22 ± 4.44
MIDAS	83.78 ± 117.97
HIT-6	59.42 ± 8.29

Note: Clinical characteristics and psychometric scores of investigated NDPH patients.
SD: standard deviation; NRS: numeric ranking scale; TTH: tension type headache; BDI II: Beck Depression Inventory II; HADS: Hospital Anxiety and Depression Scale; MIDAS: Migraine Disability Assessment; HIT-6: Headache Impact Test.

Post hoc – power analysis

Exploratory analysis with lowered threshold identified the right somato-sensory cortex as a candidate region for GM decrease and the left hippocampus for GM increase. Power analysis results for these regions and for three different previously published headache VBM studies (cluster headache, chronic migraine, and vestibular migraine) are given in Table 3.

Discussion

We were unable to detect any brain structural alterations in patients with NDPH. To the best of our knowledge, this is the first attempt to find grey matter changes in this very rare headache disorder. The study is reasonably sized and was conducted very carefully with recent software and generally accepted algorithms. In order to reconfirm our study results, we decided to perform four different analytic approaches at three different sites, which reassured the negative finding. This may seem to be in contrast to previous findings in different pain and headache disorders but matches current study results in migraine.

Headache disorders do not necessarily lead to structural brain alterations

The first study showing structural alterations in headache disorders was published in 1999 (6). Since then, several studies described structural brain changes in different headache disorders. These changes were widespread and widely overlapped across different headache disorders and pain conditions but were not consistent and negative findings often remained unpublished (e.g. (37)).

Certain structures were even considered to be specific for particular disorders (e.g. the hypothalamus for cluster headache). Most authors interpreted the "consistent" findings as being an epiphenomenon or reaction to pain attacks rather than the origin of the disease, as comparable alterations were also seen in other disorders and some even resolved after cessation of pain (17,19). Later, some of these changes were considered as the signature of pain.

The best-studied headache disorder by far is migraine. At least 27 high-quality VBM studies have been performed in recent years (38), and widespread grey matter alterations with certain overlap were reported in most studies but never clearly reproducible findings. Coordinate-based meta-analysis (CBMA) is able to objectively identify consistent and reliable findings across different studies. Several CBMA were conducted, but results were inconsistent (39). Two very recent CBMA analyses questioned the existence of a morphological signature for migraine using the latest algorithms for CBMA, applying seed-based mapping with permutation of subject images (SDM-PSI). Wang and colleagues collected a dataset of 32 VBM studies (1252 patients and 1025 HCs) and found no evidence of consistent GM alterations in migraine (39). Sensitivity analysis, subgroup meta-analyses, and meta-regression analyses suggested this result to be robust. Sheng and colleagues investigated 27 studies (1086 migraineurs with mean illness duration of 15.1 years and 877 HCs) (38). Interestingly, 16 of these datasets had already detected no changes in grey matter volume/density after applying correction for multiple comparisons. The pooled meta-analysis also found no consistent findings regarding grey matter alterations applying threshold-free cluster enhancement (TFCE) ($p < 0.05, < 10$ voxels). Furthermore, an uncorrected analysis ($p < 0.005; < 10$ voxels) remained negative. Taken together, recent CBMA analyses were not able to detect consistent grey matter alterations in migraine.

Table 3. Exploratory post hoc power analysis.

Condition	n (patients + HC)	T	Power	Virtual necessary n (group size)
NDPH – GM decrease MNI: 41 −42 63	46 (23 + 23)	3.05	86.21084 %	64 (32)
NDPH – GM increase MNI: −36 −8 −18		3.11	91.24984 %	54 (27)
Post hoc power analysis newly calculated for studies previously published				
Cluster headache Reference: (7)	169 (91 + 78)	5.59	99.98489 %	72 (36)
Chronic migraine Reference: (16)	42 (21 + 21)	6.34	99.99939 %	16 (8)
Vestibular migraine Reference: (36)	34 (17 + 17)	6.86	99.99995 %	12 (6)

Note: Exploratory post hoc power analysis performed for grey matter (GM) decrease (somatosensory cortex) and increase (hippocampus); additionally, data derived from previous studies on cluster headache, chronic migraine and vestibular migraine were calculated (for details see Methods). NDPH: new daily persistent headache; HC: healthy controls; MNI: coordinates according to the Montreal neurological Institute.

While migraine is very well studied, less data existed on chronic migraine. Because of the frequency of headache, this condition might be a better reference to NDPH. In fact, one study in chronic migraine could show that the increase in grey matter correlates positively with headache days (16). In contrast, another study could not find changes applying FWE correction. Ultimately, both studies were included in negative CBMA studies. Whether chronic migraine leaves its signature in the brain structure while episodic migraine does not cannot be answered with certainty. At a comparable time with a similar number of studies on migraine in general, there would have been no doubt about the validity of such findings, but the CBMAs now available suggest that this would have been a misjudgment. Further research is needed to bring clarification regarding brain structural alterations in chronic migraine.

It was also suggested that cross-sectional studies may cause false positive findings. A very recent study addressed this issue by investigating chronic migraine patients longitudinally and was likewise unable to show significance GM alterations (40).

Brain structural alterations detected by VBM may require genuine neural plasticity or dynamic influences

Without doubt true neural plasticity, as it occurs in learning, leads to brain structural alterations detectable using VBM (41). The underlying neural mechanisms of GM changes seen in several VBM studies on pain and headache remain unknown. It is well possible that in cross-sectional studies non-plastic alterations were depicted such as water shift-induced shrinking of cells or swelling of cells that are well known to influence MRI signal intensity (42). On this basis, even very short-term VBM alterations following a photo stimulation as short as 10 min are detectable (20). As investigators cannot control for any influence, these mechanisms may be a reason why alterations are mainly detected in cross-sectional studies, while longitudinal studies are only seldom able to detect GM changes in pain and headache disorders.

Furthermore, brain structural alterations caused by headache disorders may need dynamic influence (e.g. headache attacks) to be detectable. NDPH patients often suffer constant head pain and therefore comparable alterations may remain absent.

Structural alterations may be absent as NDPH not be one uniform headache entity

Previous research raised the question of whether NDPH is one uniform disease entity or simply a secondary symptom of an underlying disorder. According to ICHD-3, secondary headaches such as acute headache attributed to traumatic injury and headache attributed to increased or reduced cerebrospinal fluid pressure must be ruled out (21). Nevertheless, in most case-series, approximately half of the patients reported triggering events. These included infections, stress, and medical procedures (often involving anesthesia). The pathophysiology of NDPH is unresolved. There are various hypotheses about potential trigger factors and their influences on pathogenesis. Some authors postulated different herpes infections (EBV, CMV or HSV) as a possible trigger (43–46), others discussed mild head injuries, surgical procedures or toxic exposures (47). Additionally, NDPH is often associated with depression and anxiety disorders (48). All this may be seen as in contrast to a true primary headache disorder; nevertheless, it remains possible that new daily persistent

headache is not a unique entity and thus does not have any specific brain signature detectable. by VBM.

Similar accounts for the observed subtypes (TTH, PM, CM). Theoretically, it would be possible that only one of those is associated with structural alterations whereas the others are not. This could lead to false negative findings in the overall cohort. Nevertheless, this appears unlikely and at least a common signature of pain would be expected.

In this study, macroscopic brain structural alterations were more frequent in the headache cohorts compared to the control group. One could interpret this as a hint towards secondary causes. This appears unlikely, as even in the patient cohort structural alterations did not exceed the number expected from previous MRI studies (e.g. small pineal cyst in healthy volunteers of up to 23%) (49). Changes were diverse, and furthermore the pathologies seen are not suspected to cause headaches (e.g. brain atrophy and subcortical vascular encephalopathy).

Limitations

Some limitations must be addressed. In cross-sectional studies, patients and controls often cannot be matched in every dimension. This not only accounts for age and gender, which in our study was sufficiently addressed, but also for innumerable other factors including social status, psychological, and somatic (maybe subclinical) comorbidities. This may be more of an issue for positive findings, and may be the case for some previous, possibly false positive studies in primary headache disorders, as it is highly unlikely that alterations caused by these factors exactly counteract those of NDPH and thereby erase positive findings. Similar accounts for other factors we did not control for (e.g. psychological scores and used medications).

Sample size may be another point of concern, but NDPH is a very rare headache disorder and comparable sample sizes were previously evaluated being sufficient in other headache disorders. Post hoc power analysis was performed for exploratory reasons. Results need to be interpreted very carefully, as this approach in general is highly debated (50) and no generally accepted approach is available for VBM. Furthermore, the approach used can only reflect voxel level. Moreover, the calculated necessary sample sizes derived from previous studies vary a lot. Nevertheless, the power calculated for NDPH appears acceptable with chance of not making a type II error of 91%.

Conclusion

We investigated a reasonably sized cohort of NDPH patients using state-of-the-art MRI techniques but were unable to find differences in grey matter brain structure. This may be specific for NDPH, but may also support the recent discussion about the general absence of genuine grey matter changes in primary headache disorders. Future research will have to determine the role of structural brain changes for the pathophysiology of NDPH and other primary headache disorders.

Key findings

- No grey matter changes could be detected in NDPH versus healthy control subjects using VBM.
- This enriches the discussion regarding a general absence of genuine grey matter changes in primary headache disorders.
- But the finding may also be specific for NDPH, reflecting the absence of dynamic influence and/or the possibility that it is not one unique entity and thus does not have any specific brain signature detectable by VBM.

Acknowledgments

We would like to thank all study participants for their patience and endurance.

Author contributions

SN, MO, DH and KS conceptualised the experimental design. JZ, KS and SN organised and performed the study and acquired the data. SZ double-checked MRIs regarding pathologies and image quality. SN and JK analysed the data using SPM. AH performed the blinded, FSL-based analysis. SN and CMW analysed the surface data using SPM. SN, DH and JK interpreted the findings. SN and JK wrote the first draft of the manuscript. HCD and CK critically revised the manuscript. All authors gave significant input to the manuscript.

Declaration of conflicting interests

The authors declared no potential conflicts of interest with respect to the research, authorship, and/or publication of this article.

Funding

The authors received no financial support for the research, authorship and/or publication of this article.

ORCID iDs

Steffen Naegel https://orcid.org/0000-0003-1727-9362
Hans-Christoph-Diener https://orcid.org/0000-0002-6556-8612

References

1. Grande RB, Aaseth K, Lundqvist C, et al. Prevalence of new daily persistent headache in the general population. The Akershus study of chronic headache. *Cephalalgia* 2009; 29: 1149–1155.
2. Vanast WJ. New daily persistent headaches: Definition of a benign syndrome (abstract). *Headache* 1986; 26: 318.
3. Headache Classification Subcommittee of the International Headache Society. The International Classification of Headache Disorders, 2nd edition. *Cephalalgia* 2004; 24: 9–160.
4. Goadsby PJ. New daily persistent headache: A syndrome, not a discrete disorder. *Headache* 2011; 51: 650–653.
5. Li D and Rozen TD. The clinical characteristics of new daily persistent headache. *Cephalalgia* 2002; 22: 66–69.
6. May A, Ashburner J, Büchel C, et al. Correlation between structural and functional changes in brain in an idiopathic headache syndrome. *Nat Med* 1999; 5: 836–838.
7. Naegel S, Holle D, Desmarattes N, et al. Cortical plasticity in episodic and chronic cluster headache. *NeuroImage: Clin* 2014; 6: 415–423.
8. Absinta M, Rocca MA, Colombo B, et al. Selective decreased grey matter volume of the pain-matrix network in cluster headache. *Cephalalgia* 2012; 32: 109–115.
9. Obermann M, Holle D and Nagel S. Functional neuroimaging in trigeminal autonomic cephalalgias. *Ann Indian Acad Neurol* 2018; 21: S51–S56.
10. Jin C, Yuan K, Zhao L, et al. Structural and functional abnormalities in migraine patients without aura. *NMR Biomed* 2013; 26: 58–64.
11. Kim JH, Suh S-I, Seol HY, et al. Regional grey matter changes in patients with migraine: A voxel-based morphometry study. *Cephalalgia* 2008; 28: 598–604.
12. Schmidt-Wilcke T, Leinisch E, Straube A, et al. Gray matter decrease in patients with chronic tension type headache. *Neurology* 2005; 65: 1483–1486.
13. Riederer F, Marti M, Luechinger R, et al. Grey matter changes associated with medication-overuse headache: Correlations with disease related disability and anxiety. *World J Biol Psychiatry* 2012; 13: 517–525.
14. Riederer F, Gantenbein AR, Marti M, et al. Decrease of gray matter volume in the midbrain is associated with treatment response in medication-overuse headache: Possible influence of orbitofrontal cortex. *J Neurosci* 2013; 33: 15343–15349.
15. Riederer F, Gantenbein AR, Marti M, et al. Grey matter changes in medication-overuse headache before and after medication withdrawal. *J Headache Pain* 2013; 14: P177.
16. Neeb L, Bastian K, Villringer K, et al. Structural gray matter alterations in chronic migraine: Implications for a progressive disease? *Headache* 2017; 57: 400–416.
17. Obermann M, Nebel K, Schumann C, et al. Gray matter changes related to chronic posttraumatic headache. *Neurology* 2009; 73: 978–983.
18. Gwilym SE, Filippini N, Douaud G, et al. Thalamic atrophy associated with painful osteoarthritis of the hip is reversible after arthroplasty: A longitudinal voxel-based morphometric study. *Arthritis Rheum* 2010; 62: 2930–2940.
19. Rodriguez-Raecke R, Niemeier A, Ihle K, et al. Brain gray matter decrease in chronic pain is the consequence and not the cause of pain. *J Neurosci* 2009; 29: 13746–13750.
20. Naegel S, Hagenacker T, Theysohn N, et al. Short latency gray matter changes in voxel-based morphometry following high frequent visual stimulation. *Neural Plast* 2017; 2017: 1397801.
21. Headache Classification Committee of the International Headache Society. The International Classification of Headache Disorders, 3rd edition. *Cephalalgia* 2018; 38: 1–211.
22. Headache Classification Committee of the International Headache Society. The International Classification of Headache Disorders, 3rd edition (beta version). *Cephalalgia* 2013; 33: 629–808.
23. Ashburner J. A fast diffeomorphic image registration algorithm. *Neuroimage* 2007; 38: 95–113.
24. Ashburner J and Friston K. Multimodal image coregistration and partitioning – a unified framework. *Neuroimage* 1997; 6: 209–217.
25. Friston KJ. Commentary and opinion: II. Statistical parametric mapping: Ontology and current issues. *J Cereb Blood Flow Metab* 1995; 15: 361–370.
26. Wright IC, McGuire PK, Poline JB, et al. A voxel-based method for the statistical analysis of gray and white matter density applied to schizophrenia. *Neuroimage* 1995; 2: 244–252.
27. Good CD, Johnsrude IS, Ashburner J, et al. A voxel-based morphometric study of ageing in 465 normal adult human brains. *Neuroimage* 2001; 14: 21–36.
28. Ashburner J and Friston KJ. Unified segmentation. *Neuroimage* 2005; 26: 839–851.
29. Douaud G, Smith S, Jenkinson M, et al. Anatomically related grey and white matter abnormalities in adolescent-onset schizophrenia. *Brain* 2007; 130: 2375–2386.
30. Good CD, Johnsrude I, Ashburner J, et al. Cerebral asymmetry and the effects of sex and handedness on brain structure: A voxel-based morphometric analysis of 465 normal adult human brains. *Neuroimage* 2001; 14: 685–700.
31. Smith SM, Jenkinson M, Woolrich MW, et al. Advances in functional and structural MR image analysis and implementation as FSL. *Neuroimage* 2004; 23: S208–S219.
32. Nichols TE and Holmes AP. Nonparametric permutation tests for functional neuroimaging: A primer with examples. *Hum Brain Mapp* 2001; 15: 1–25.
33. Smith SM and Nichols TE. Threshold-free cluster enhancement: Addressing problems of smoothing, threshold dependence and localisation in cluster inference. *Neuroimage* 2009; 44: 83–98.

34. Dahnke R, Yotter RA and Gaser C. Cortical thickness and central surface estimation. *Neuroimage* 2013; 65: 336–348.
35. Faul F, Erdfelder E, Lang A-G, et al. G*Power 3: A flexible statistical power analysis program for the social, behavioral, and biomedical sciences. *Behav Res Methods* 2007; 39: 175–191.
36. Obermann M, Wurthmann S, Steinberg BS, et al. Central vestibular system modulation in vestibular migraine. *Cephalalgia* 2014; 34: 1053–1061.
37. Matharu, MS. Functional and structural neuroimaging in primary headache disorders. PhD thesis. University College London, London, UK. https://www.ucl.ac.uk/library/.
38. Sheng L, Zhao P, Ma H, et al. A lack of consistent brain grey matter alterations in migraine. *Brain* 2020; 143: e45.
39. Wang HZ, Wang WH, Shi HC, et al. Is there a reliable brain morphological signature for migraine? *J Headache Pain* 2020; 21: 89.
40. Mehnert J, Schulte L and May A. No grey matter alterations in longitudinal data of migraine patients. *Brain* 2020; 143: e93.
41. Draganski B, Gaser C, Kempermann G, et al. Temporal and spatial dynamics of brain structure changes during extensive learning. *J Neurosci* 2006; 26: 6314–6317.
42. Stroman PW, Lee AS, Pitchers KK, et al. Magnetic resonance imaging of neuronal and glial swelling as an indicator of function in cerebral tissue slices. *Magn Reson Med* 2008; 59: 700–706.
43. Peng K-P, Fuh J-L, Yuan H-K, et al. New daily persistent headache: Should migrainous features be incorporated? *Cephalalgia* 2011; 31: 1561–1569.
44. Diaz-Mitoma F, Vanast WJ and Tyrrell DL. Increased frequency of Epstein-Barr virus excretion in patients with new daily persistent headaches. *Lancet* 1987; 1: 411–415.
45. Hamada T, Ohshima K, Ide Y, et al. A case of new daily persistent headache with elevated antibodies to Epstein-Barr virus. *Jpn J Med* 1991; 30: 161–163.
46. Meineri P, Torre E, Rota E, et al. New daily persistent headache: Clinical and serological characteristics in a retrospective study. *Neurol Sci* 2004; 25: S281–S282.
47. Rozen TD. Triggering events and new daily persistent headache: Age and gender differences and insights on pathogenesis – a clinic-based study. *Headache* 2016; 56: 164–173.
48. Peres MFP, Lucchetti G, Mercante JPP, et al. New daily persistent headache and panic disorder. *Cephalalgia* 2011; 31: 250–253.
49. Pu Y, Mahankali S, Hou J, et al. High prevalence of pineal cysts in healthy adults demonstrated by high-resolution, noncontrast brain MR imaging. *Am J Neuroradiol* 2007; 28: 1706–1709.
50. Hoenig JM and Heisey DM. The abuse of power. *Am Stat* 2001; 55: 19–24.

DOI: 10.1177/03331024211045653
URN: urn:nbn:de:hbz:465-20230524-130347-4