Full Length Article

JHS(E)

Journal of Hand Surgery
(European Volume)
2020, Vol. 45(6) 629–635

DOI: 10.1177/1753193419899037
journals.sagepub.com/home/jhs
SAGE

Limb preserving surgery for soft-tissue sarcoma in the hand: a retrospective study of 51 cases

Mehran Dadras[1], Hans-Ulrich Steinau[1,2], Ole Goertz[1,3], Marcus Lehnhardt[1], Björn Behr[1] and Kamran Harati[1]

Abstract

Our retrospective study analysed the long-term results of a conservative limb-preserving surgical strategy in 51 patients with soft-tissue sarcoma of the hand from a single institution. We assessed survival and prognostic factors, including the surgical margins. No transradial amputations were performed. Microscopically free resection margins were obtained in 45 of the patients. The remaining six patients had microscopically incomplete resection. Forty-four surviving patients had a median follow-up of 6.5 years (range 12–307), and one patient had no follow-up beyond 3 months following surgery. Among those patients, 29 had more than 5 years of follow-up. Five-year local-recurrence-free survival was 65%, metastasis-free survival was 84%, and disease-specific survival was 91%. Tumour size was predictive of all outcome parameters, but positive resection margins adversely affected local recurrence only. Survival was similar to the survival after a more radical surgical approach reported in the literature.

Level of evidence: IV

Keywords

Sarcoma, tumour, amputation, soft tissue sarcoma

Date received: 25th August 2019; revised: 3rd December 2019; accepted: 11th December 2019

Introduction

Soft-tissue sarcomas (STSs) of the hand represent a rare subgroup of all STSs and constitute a clinical challenge to limb-preserving therapy (Pradhan et al., 2008). Surgical resection represents the cornerstone of STS treatment and is potentially curative. Typically, wide excision, resecting more than 1 cm of surrounding healthy tissue, is aimed for (Pignatti and Campanacci, 1992; Rosenberg et al., 1982). While the impact of margin status on local recurrence has been shown in multiple studies, the implications of the width of negative surgical margins, and the subsequent association of local recurrence with survival, remains controversial (Gronchi et al., 2010; Harati et al., 2017; Lehnhardt et al., 2019; Pisters et al., 1996; Potter et al., 2013; Zagars et al., 2003). The use of adjuvant radiotherapy has been shown to reduce local recurrence (Schreiber et al., 2012) and has supported conservative surgical treatment in the hand (Talbert et al., 1990). Isolated limb perfusion (ILP) is another modality that allows conservative resection (Jakob et al., 2014).

Our retrospective study aimed at analysing the long-term results of a conservative limb preserving surgical strategy used in a single institution. We assessed survival and prognostic factors, including the surgical margins.

[1]Department of Plastic Surgery and Hand Surgery, BG University Hospital Bergmannsheil, Bochum, Germany
[2]University Clinic Essen – Tumor Center of West-Germany/ Sarcoma Center, University of Essen, Essen, Germany
[3]Department of Plastic, Reconstructive and Aesthetic Surgery, Martin-Luther-Hospital, Berlin, Germany

Corresponding Author:
Kamran Harati, Department of Plastic Surgery and Hand Surgery, BG University Hospital Bergmannsheil, Bürkle de la Camp-Platz 1, 44789 Bochum, Germany.
Email: kamran.harati@t-online.de

Methods

Patient and data selection

This retrospective study was approved by our local ethical committee. All patients treated for a STS of the hand in our institution between 1995 and 2016 were identified from medical records. Tumour location in the hand was defined as distal to the ulnar styloid. Demographic, clinical, and outcome data were obtained from the medical records. Additional outcome data were obtained by correspondence with patients or family members.

Primary outcomes were 5-year local recurrence-free survival, 5-year metastasis-free survival, and 5-year disease-specific survival. Local-recurrence-free survival was calculated from the date of resection until tumour recurrence or until last follow-up in patients without recurrence. Metastasis-free survival was calculated from date of resection until occurrence of metastases or until last follow-up in patients without metastasis. Disease-specific survival was calculated from the date of resection until death by known present disease or last follow-up in patients without disease-specific death. Overall survival was also calculated.

Treatment

Preoperatively, contrast-enhanced MRI of the tumour site and computed tomography scans of the chest were routinely performed. The surgical aim for all patients was complete resection of the primary tumour with microscopically negative margins and preservation of as much hand tissue and function as possible. Tumours with restricted possibility of limb preserving resection and tumours with insufficient resection and unclear margins adjacent to functionally relevant structures were assessed for ILP with Melpahalan and tumour necrotic factor (TNF)-α (Steinau et al., 2015).

In epifascial lesions, a deep clear margin of one fascial layer was sought. Vascular or neural reconstruction and/or tendon transfers were performed as needed. Skin grafts and local or free flaps were used for coverage. Figure 1 shows an example with tendon and soft-tissue reconstruction. Radiation or chemotherapy was given as decided by our interdisciplinary tumour board.

The follow-up management for all patients included clinical examination, radiograph of the chest, and contrast-enhanced MRI of the tumour site every 3 months for the first 2 years, and then every 6 months for the next 3 years. Further MRI and radiographic examination could be done in the following 5 years based on tumour properties and the decision of the informed patient.

Microscopic assessment of resection margins

Surgical margins were assessed after fixation of the pathologic specimen with formalin and dyeing the surface with ink. All pathology slides and the according surgical margin widths were analysed and reviewed for consensus diagnosis by an experienced soft-tissue pathologist from our institution. Margin quality was reported following the R-classification with R0 representing microscopically negative and R1 representing microscopically positive (involved) surgical margins (Gundle et al., 2018).

Statistics

Data are presented as means and standard deviation or median.

For survival analyses we used Kaplan–Meier log-rank tests and multivariate Cox regression with backwards elimination of factors with $p < 0.01$ in log-rank testing. Hazard ratio (HR) was calculated and is presented as (95% confidential interval, CI). $p < 0.05$ was considered as statistically significant.

Results

Patients

After exclusion of one patient due to metastatic disease when first seen, 51 patients were included in the study. Six patients initially presented at our institution with a recurrence but with complete data on primary treatment, and 28 were referred after incomplete excision. Twenty-eight patients were men and 23 women. Mean age at first operation was 41 years (SD 19). Thirty-three tumours were deep (below fascia), 24 were located in the metacarpal area, 18 in the wrist, and nine in the fingers. Mean maximum tumour diameter was 2.2 cm (SD 1.8), with 30 tumours being smaller than 1.5 cm and seven larger than 5 cm. The most prevalent histologic subtype was synovial sarcoma in 13 tumours, followed by epitheloid sarcoma in seven, liposarcoma in six, undifferentiated pleomorphic sarcoma in five, and leiomyosarcoma in three. Of the six liposarcomas, four were myxoid and two were pleomorphic. The remaining 17 tumours consisted of different subtypes, such as myxofibrosarcoma ($n = 3$), extra-skeletal chondrosarcoma ($n = 3$), clear cell sarcoma ($n = 2$), malignant nerve sheath tumour ($n = 2$), primitive neuroectodermal tumours ($n = 2$), dermatofibrosarcoma protuberans ($n = 2$), rhabdomyosarcoma ($n = 2$), and fibrosarcoma ($n = 1$). Sixteen tumours were low grade (G1), 25 were G2 and 10 were G3.

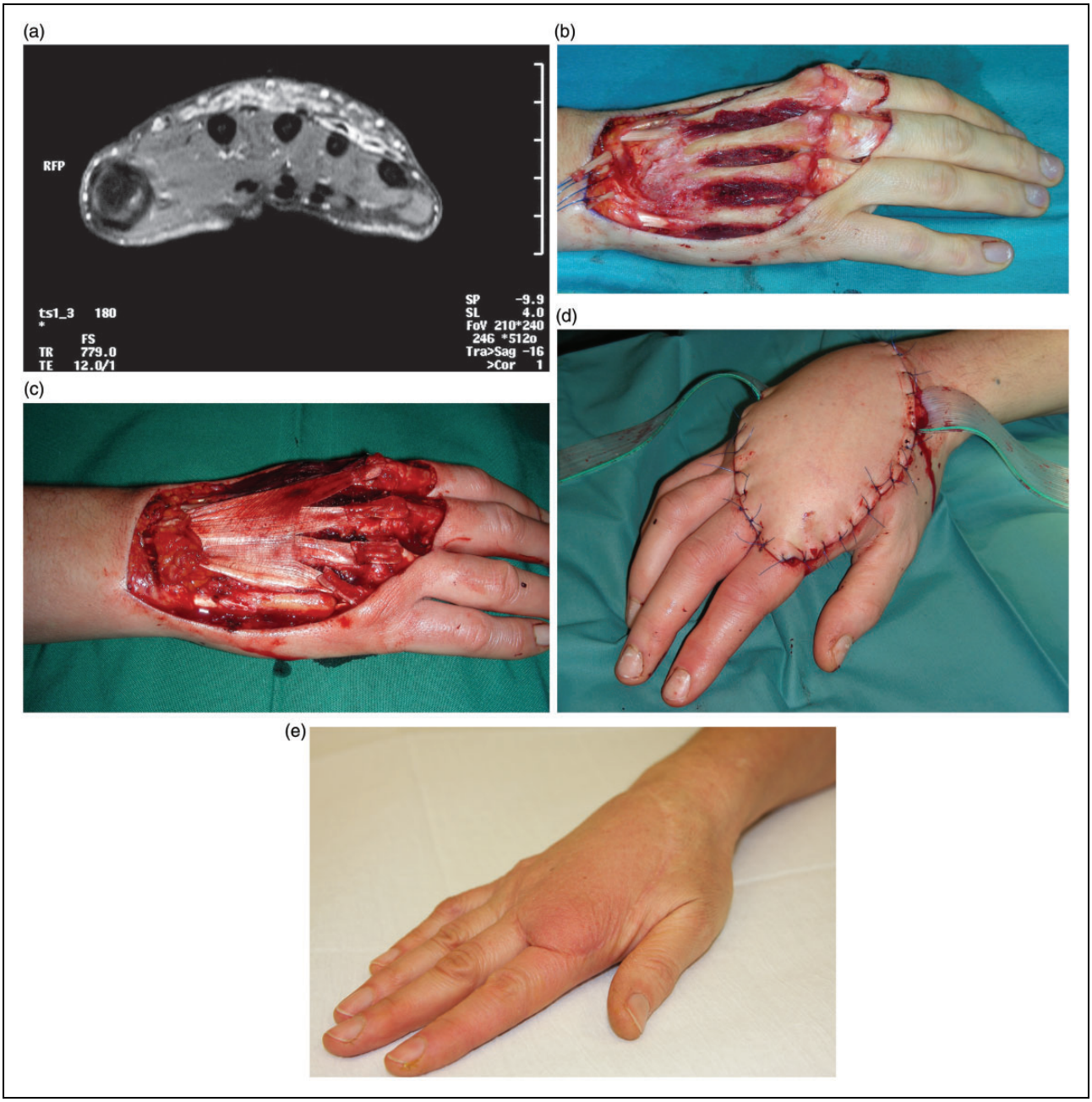

Figure 1. (a) Dermatofibrosarcoma protuberans on the dorsum of the hand with infiltration of the extensor tendons on MRI scan. (b) Resection of the tumour including extensor tendons and the metacarpal periosteum of digits 2–5. (c) Reconstruction of extensor tendons with tensor fascia lata. (d) Soft-tissue coverage with a free anterolateral thigh flap. (e) Results at 10 years after surgery.

Clinical treatment

Neoadjuvant therapy was administered to 15 patients, 13 of these received ILP of which two additionally received radiation therapy.

Resection included tendons or nerves in 22 cases and additionally bone in another nine cases. Two patients received finger amputations and one patient a single-ray amputation. No transradial amputations were performed. In patients with resection of tendons, nerves, and bone, primary reconstructions included tendon transfers or autologous tendon grafts, nerve grafts, autologous bone grafts, and arthrodeses.

A complete resection (clear final surgical margins, R0) was achieved in 45 of the patients. The remaining six patients had microscopically incomplete resection (R1). Of these, two had received treatment of

the primary tumour outside our institution. Of the 45 patients with clear margins (R0), wide margins (>1 cm) were present in four patients, while close margins (<1 cm) were present in 41 patients. Wound coverage was achieved by simple suturing in 29 patients, local flaps in 19 patients, and with free vascularized flaps in three patients. Adjuvant radiation therapy was given to 17 patients (33%) with a median dose of 60 Gray. This included all three patients in whom no clear surgical margins were achieved during resection at our institution. Fifteen of the radiated patients had high-grade tumours.

Complications as classified higher than two by Clavien-Dindo et al. (2004) occurred in six patients: two developed haemorrhage needing operative revision, three patients developed wound dehiscence or infection of whom one needed reoperation, and one patient developed a bronchial infection.

Follow-up

Forty-four surviving patients had a median follow-up of 6.5 years (range 12–307 months), and one patient had no follow-up beyond 3 months after surgery. Among those patients, 29 had more than 5 years of follow-up. Eighteen patients had developed a recurrence, eight patients had developed metastases, and six patients had died. The sarcoma was considered to be the cause of death in four of these six patients. All four patients had developed pulmonary metastases, and none had local recurrence. Results of univariate analysis of predictors of 5-year local recurrence-free survival, 5-year metastasis-free survival and 5-year disease-specific survival are presented in the online supplementary Table S1.

Local recurrence

Estimated 5-year and 10-year local-recurrence-free survival was 65% (SD 8) and 51% (SD 9), respectively. A Kaplan–Meier curve of the 5-year local-recurrence-free survival is presented in Figure 2. Among the 18 patients with local recurrence, 12 had a single recurrence, two patients had two recurrences, four patients had three recurrences, and one patient had four local recurrences. Factors associated with 5-year local-recurrence-free survival in univariate log-rank analysis were tumour location, histologic subtype, tumour size, resection margins, and adjuvant radiation therapy.

In multivariate Cox regression analysis, we identified the following predicting factors of 5-year local-recurrence-free survival: metacarpal location with a HR of 6 (2–20) ($p = 0.003$), tumour size with a HR of 7 (2–28) ($p = 0.006$) for tumours >5 cm compared with tumours <1.5 cm, positive resection margins with a HR of 5 (2–18) ($p = 0.009$), and histologic subtypes summarized as 'other', with a HR of 9 (3–33) ($p < 0.001$). 'Other' included malignant nerve sheath tumour, clear cell sarcoma, and fibrosarcoma.

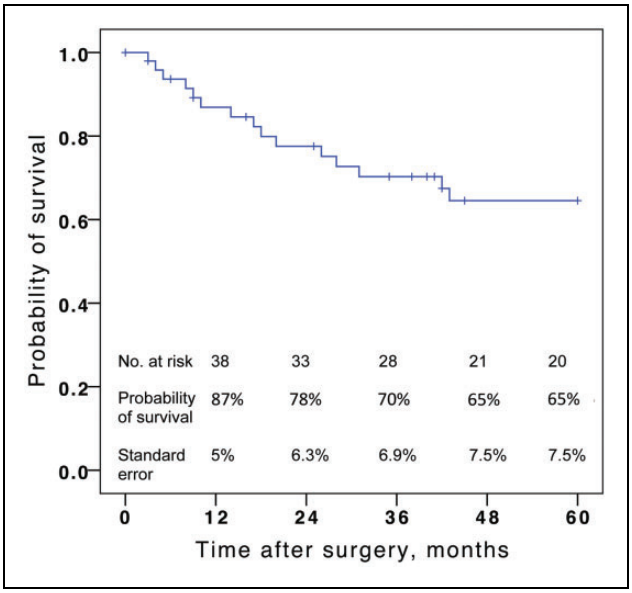

Figure 2. Kaplan–Meier curve of the 5-year local-recurrence-free survival.

Metastasis-free survival

Estimated 5-year and 10-year metastasis-free survival was 84% (SD 6) and 80% (SD 7), respectively. A Kaplan–Meier curve of the metastasis-free survival is shown in Figure 3. For patients who developed metastases, six were in the lungs, one in a vertebra, one in regional lymph nodes, and one in the skin of the proximal forearm. The only factor that was found to have a notable impact on metastasis-free survival in univariate analysis was age. Microscopically incomplete resection (R1) was not associated with lower metastasis-free survival as no metastases were observed in the R1 subcohort. Likewise, close resection margins did not significantly alter the 5-year metastasis-free survival in the R0 subcohort. Tumour size larger than 5 cm was the only significant predictor of metastasis-free survival in multivariate analysis with a HR of 5 (1–20) ($p = 0.043$).

Disease-specific survival

Estimated 5-year and 10-year disease-specific survival as well as overall survival was 91% (SD 5). A Kaplan–Meier curve of the disease-specific survival is presented in Figure 4. Analysis of predictors was limited by the occurrence of only four events in the

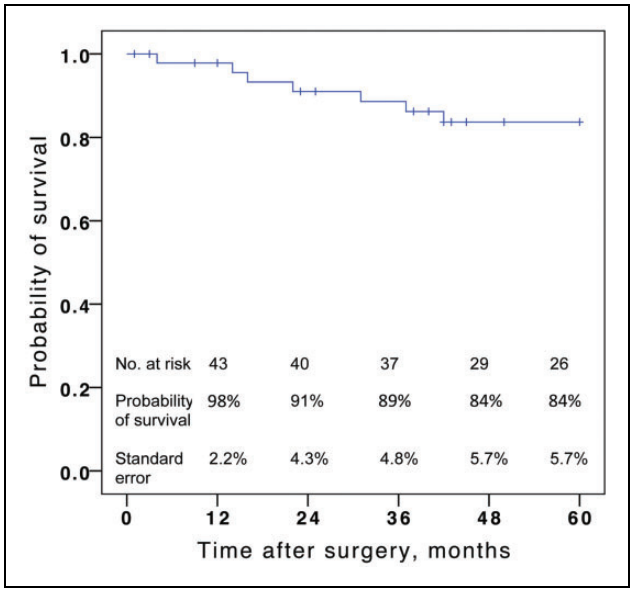

Figure 3. Kaplan–Meier curve of the 5-year metastasis-free survival.

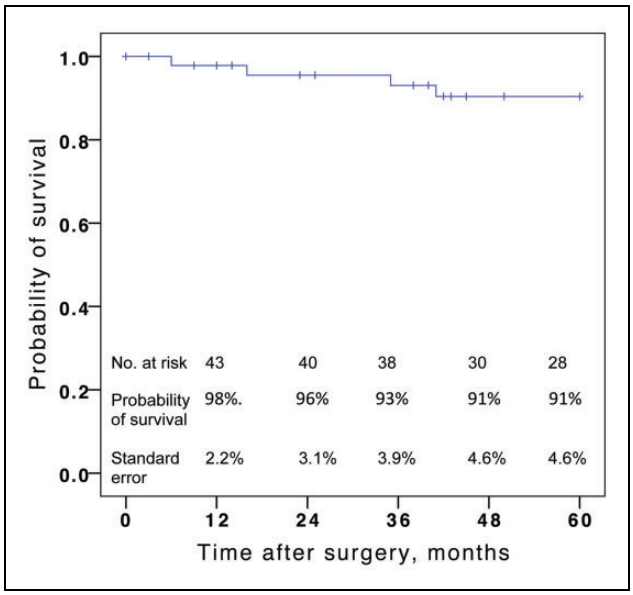

Figure 4. Kaplan–Meier curve of the 5-year disease-specific survival.

follow-up period. Tumour size could be identified as a predictive factor in multivariate analysis with a HR of 13 (1–124) ($p = 0.03$) for tumours larger than 5 cm.

Limb preservation

Amputations of fingers or single rays were performed as primary tumour treatment in three patients. In no patient, primary transradial amputation was performed. Upon first recurrence, one patient received a single-ray amputation and another patient a transradial amputation. The other patients with recurrence were treated with limb preserving surgery. Treatment of the last local recurrence in seven patients with multiple recurrences consisted of single-ray amputations in two cases and of transradial amputation in two cases. Ultimately, transradial amputation was performed in three patients, in average 95 months (SD 82) after primary resection.

Discussion

We performed an analysis of 51 STSs of the hand treated in a single institution and were able to show an association of tumour size and quality of surgical margins with local recurrence. No significant impact of surgical margins with metastasis-free survival or disease-specific survival could be established. Most tumours were high-grade, and as in other studies, epitheloid sarcoma and synovial sarcoma were among the most frequent histologic subtypes (Houdek et al., 2017; Lans et al., 2019). Tumour size was also identified as an important overall prognostic factor and predictive of local recurrence-free survival, metastasis-free survival, and disease-specific survival, which also has been reported previously (Houdek et al., 2017; Lans et al., 2019). They reported wide excision of 41 out of 46 hand STSs, of which six were transradial amputations and 19 were single or multiple ray amputations. At a mean follow-up of 5 years they reported a local-recurrence-free survival of 86%, metastasis-free survival of 66%, and overall survival of 78%. In a study by Lans et al. (2019) of 64 hand with STS, of which 83% were referred after external unplanned excision, amputations were performed in approximately 44% of cases. They reported a 5-year disease-free survival of 69% and 5-year overall survival of 82% after a median follow-up of 4 years (Lans et al., 2019). Pradhan et al. (2008) reported local-recurrence-free survival of 63%, metastasis-free survival of 74%, and overall survival of 87% at 5 years in 64 patients with hand STS after a mean follow-up of 4 years. Amputations were performed in 30%, and attempted wide resection when the tumour involved the resection margins was performed in 42% of the remaining cases. Of note, mean maximum tumour diameter was higher in all three cited studies (mean 2.7 cm, median 3 cm, and mean 4 cm, respectively, versus a mean of 2.2 cm in our study), and none of the studies reported and compared actual resection margin width. Survival was higher in our study with a 5- and 10-year

disease-specific survival and overall survival of 91%, despite less comprehensive surgical resection.

In this study, we used the R staging system (Harati and Lehnhardt, 2017). Other systems exist, including the system described by Enneking et al. (1981). The intention of the R system is to be more reproducible and objective and it is widely used (Gundle et al., 2018). Positive surgical margins (R1) were predictive of local recurrence in our study, confirming large studies on STS in general (Pisters et al., 1996; Stojadinovic et al., 2002) and other studies on hand STS (Lans et al., 2019; Pradhan et al., 2008). Yet, there was no significant impact of margin status on metastasis-free survival or disease-specific survival. Gronchi et al. (2010) analysed the outcome of 997 surgically treated patients with extremity STS and revealed that the local outcome of proximal tumours directly influenced survival by invading the abdomen and the thorax. However, they could not find an association between local recurrence control and survival for distal extremity STS (Gronchi et al., 2010). Lin et al. (2002) analysed the outcome of 115 hand and foot STS. In their series, local recurrence in the distal extremities was not associated with a higher rate of distant metastases and, therefore, did not impact disease-specific survival. Hence, the authors concluded that local residual disease and distant metastatic disease were independent predictive factors and did not influence each other. Neither Mattei et al. (2019) with 205 distal extremity STS, nor Harati et al. (2016) with 120 distal lower extremity STS found any association between positive resection margins and distant recurrence or overall survival.

One limitation of our study is the low statistical power due to a relatively small number of cases, which results from the rarity of STS in the hand. Also, only patients without initial dissemination and who received operative treatment were included. This and the smaller tumour size hamper comparison with other studies. Conservative surgical treatment with the aim of limb-preserving complete resection (R0) with close margins represents a viable treatment option for STS of the hand. The different surgical treatment options should be discussed with patients with STS of the hand, paying attention to tumour characteristics and preferences of the informed patient. Since postoperative radiation is significantly associated with better local-recurrence-free survival, we recommend routinely using adjuvant radiation therapy after resection of high-grade sarcomas or definite intralesional resection, in line with the German guidelines (Schütte et al., 2019).

Acknowlegement Authors Björn Behr and Kamran Harati contributed equally to this work.

Declaration of conflicting interests The authors declare no potential conflicts of interest with respect to the research, authorship, and/or publication of this article.

Funding The authors received no financial support for the research, authorship, and/or publication of this article.

Supplemental material Supplemental material for this article is available online.

References

Dindo D, Demartines N, Clavien PA. Classification of surgical complications: a new proposal with evaluation in a cohort of 6336 patients and results of a survey. Ann Surg. 2004, 240: 205–13.

Enneking WF, Spanier SS, Malawer MM. The effect of the anatomic setting on the results of surgical procedures for soft parts sarcoma of the thigh. Cancer. 1981, 47: 1005–22.

Gronchi A, Lo Vullo S, Colombo C et al. Extremity soft tissue sarcoma in a series of patients treated at a single institution: local control directly impacts survival. Ann Surg. 2010, 251: 506–11.

Gundle KR, Kafchinski L, Gupta S et al. Analysis of margin classification systems for assessing the risk of local recurrence after soft tissue sarcoma resection. J Clin Oncol. 2018, 36: 704–9.

Harati K, Goertz O, Pieper A et al. Soft tissue sarcomas of the extremities: surgical margins can be close as long as the resected tumor has no ink on it. Oncologist. 2017, 22: 1400–10.

Harati K, Kirchhoff P, Behr B et al. Soft tissue sarcomas of the distal lower extremities: a single-institutional analysis of the prognostic significance of surgical margins in 120 patients. Oncol Rep. 2016, 36: 863–70.

Harati K, Lehnhardt M. The changing paradigm of resection margins in sarcoma resection. Innov Surg Sci. 2017, 2: 165–70.

Houdek MT, Walczak BE, Wilke BK, Kakar S, Rose PS, Shin AY. What factors influence the outcome of surgically treated soft tissue sarcomas of the hand and wrist? Hand. 2017, 12: 493–500.

Jakob J, Tunn PU, Hayes AJ, Pilz LR, Nowak K, Hohenberger P. Oncological outcome of primary non-metastatic soft tissue sarcoma treated by neoadjuvant isolated limb perfusion and tumor resection. J Surg Oncol. 2014, 109: 786–90.

Lans J, Yue KC, Castelein RM, Chen NC, Calderon SL. Soft tissue sarcoma of the hand: is unplanned excision a problem? Eur J Surg Oncol. 2019, 45: 1281–7.

Lehnhardt M, Sogorski A, Wallner C et al. [Soft tissue sarcomas: limb salvage using reconstructive plastic surgery techniques]. Chirurg. 2019, 90: 94–101.

Lin PP, Guzel VB, Pisters PW et al. Surgical management of soft tissue sarcomas of the hand and foot. Cancer. 2002, 95: 852–61.

Mattei JC, Brouste V, Terrier P et al. Distal extremities soft tissue sarcomas: are they so different from other limb localizations? J Surg Oncol. 2019, 119: 479–88.

Pignatti G, Campanacci M. Surgical approach to soft tissue sarcomas of the extremities. Ann Oncol. 1992, 3(Suppl 2): S59–61.

Pisters PW, Leung DH, Woodruff J, Shi W, Brennan MF. Analysis of prognostic factors in 1,041 patients with localized soft tissue sarcomas of the extremities. J Clin Oncol. 1996, 14: 1679–89.

Potter BK, Hwang PF, Forsberg JA et al. Impact of margin status and local recurrence on soft-tissue sarcoma outcomes. J Bone Joint Surg Am. 2013, 95: e151.

Pradhan A, Cheung YC, Grimer RJ et al. Soft-tissue sarcomas of the hand: oncological outcome and prognostic factors. J Bone Joint Surg Br. 2008, 90: 209–14.

Rosenberg SA, Tepper J, Glatstein E et al. The treatment of soft-tissue sarcomas of the extremities: prospective randomized evaluations of (1) limb-sparing surgery plus radiation therapy compared with amputation and (2) the role of adjuvant chemotherapy. Ann Surg. 1982, 196: 305–15.

Schreiber D, Rineer J, Katsoulakis E et al. Impact of postoperative radiation on survival for high-grade soft tissue sarcoma of the extremities after limb sparing radical resection. Am J Clin Oncol. 2012, 35: 13–7.

Schütte J, Bauer S, Brodowicz T et al. [Soft tissue sarcomas (malignant soft tissue tumors) of the adult]. German Society for Haematology and Oncology. 2019, https://www.onkopedia.-com/de/onkopedia/guidelines/weichgewebssarkome-maligne-weichgewebstumoren-des-erwachsenen/@@guideline/html/index.html.

Steinau HU, Farzaliyev F, Stricker I, Hauser J, Podleska LE. [Sarcoma of the hand and wrist]. Handchir Mikrochir Plast Chir. 2015, 47: 76–82.

Stojadinovic A, Leung DH, Hoos A, Jaques DP, Lewis JJ, Brennan MF. Analysis of the prognostic significance of microscopic margins in 2,084 localized primary adult soft tissue sarcomas. Ann Surg. 2002, 235: 424–34.

Talbert ML, Zagars GK, Sherman NE, Romsdahl MM. Conservative surgery and radiation therapy for soft tissue sarcoma of the wrist, hand, ankle, and foot. Cancer. 1990, 66: 2482–91.

Zagars GK, Ballo MT, Pisters PW et al. Prognostic factors for patients with localized soft-tissue sarcoma treated with conservation surgery and radiation therapy: an analysis of 1225 patients. Cancer. 2003, 97: 2530–43.

DOI: 10.1177/1753193419899037
URN: urn:nbn:de:hbz:465-20220401-120920-3

Dadras, M. et.al. (2020). Limb preserving surgery for soft-tissue sarcoma in the hand : a retrospective study of 51 cases, Journal of Hand Surgery, 45(6) 629-635 https://doi.org/10.1177/1753193419899037